Triceps Ruptures After Fluoroquinolone Antibiotics: A Report of 2 Cases

Theodore B. Shybut, MD,*† and Ernest R. Puckett, BS‡

Rupture of the triceps brachii tendon is exceedingly rare, and surgical repair is generally indicated. Fluoroquinolone antibiotics have been implicated in tendon pathology, including tendon ruptures. Triceps rupture has not been previously reported in the setting of fluoroquinolone antibiotic therapy. We present 2 cases of triceps tendon rupture after treatment with fluoroquinolones. In both cases, triceps repair was performed with good outcomes. These cases highlight a risk of fluoroquinolone-induced tendinopathy to athletes. The sports medicine team should be aware of this risk and consider it when choosing antibiotics to treat athletes.

Keywords: triceps; tendon; rupture; fluoroquinolone

A growing body of literature implicates treatment with fluoroquinolone antibiotics in tendon pathology, including tendon ruptures.[2-4,12,16,18] The Achilles tendon is the most commonly affected[18]; however, rectus femoris, adductor longus, patellar tendon, long head of the biceps, distal biceps after transfer, and rotator cuff tears have all been reported in association with fluoroquinolone antibiotic use.[5,9,14,15,19] Rupture of the triceps brachii tendon is exceedingly rare. In a review of 1014 tendon ruptures, Anzel et al[1] reported that only 0.8% were of the triceps tendon. We present 2 cases of triceps tendon rupture after treatment with fluoroquinolones.

CASE 1

A 60-year-old right-handed man sustained an isolated left elbow injury while abruptly stopping on a bicycle. His elbow flexed against the handlebar, and he felt a pop with immediate pain and associated weakness. On physical examination, his posterior arm was ecchymotic and tender to palpation, and a defect was palpable in the triceps tendon. He could not extend his elbow against gravity. Radiographs revealed a displaced fleck avulsion off the olecranon (Figure 1).

Medical history was notable for a course of levofloxacin 3 months prior to injury around the time of a prostate biopsy. Magnetic resonance imaging (MRI) showed complete triceps avulsion with retraction. Urgent open left distal triceps repair was performed using a modified double-row technique with suture anchors.

Postoperatively, the patient underwent physical therapy and home exercises following a prescribed triceps repair rehabilitation protocol. He returned to golf at 5 months. At 14 months postsurgery, he felt fully recovered and had resumed all activities without pain and with full motion and strength. Two years after surgery, he rated his strength as 5 out of 5.

CASE 2

A 47-year-old right-handed man sustained a left elbow injury competing in judo 1 month prior to presentation. He was thrown onto his flexed elbows as part of a judo falling technique called forward ukemi but landed predominantly on the left and felt a pop. His chief complaint was weakness; examination demonstrated inability to extend his elbow against gravity. He presented with an MRI that showed a full-thickness triceps tear with 7-mm retraction (Figure 2).

Plain radiographs showed a "flake sign."[3] Three months prior, the patient had been treated for epididymitis with a course of ciprofloxacin. He underwent urgent open repair using a transosseous suture technique.

Postoperatively, he underwent physical therapy and home exercises following a prescribed triceps repair rehabilitation protocol. Eight months postoperative, clinical examination demonstrated a healed repair. At 10 months, the patient had returned to participation in randori (free practice/sparring), ne-waza (ground grappling), and coaching but not open competition, noting apprehension about the possibility of recurrent injury.

From the †Department of Orthopedic Surgery, Baylor College of Medicine, Houston, TX, ‡Baylor College of Medicine, Houston, TX
*Address correspondence to Theodore B. Shybut, MD, Department of Orthopedic Surgery, Baylor College of Medicine, 7200 Cambridge Street, Suite 10A, Houston, TX 77030 (email: shybut@bcm.edu).
The authors report no potential conflicts of interest in the development and publication of this article.
DOI: 10.1177/1941738117713686
© 2017 The Author(s)

Figure 1. Lateral radiograph of the elbow demonstrating a "flake sign,"[3] indicating triceps avulsion (gray arrow).

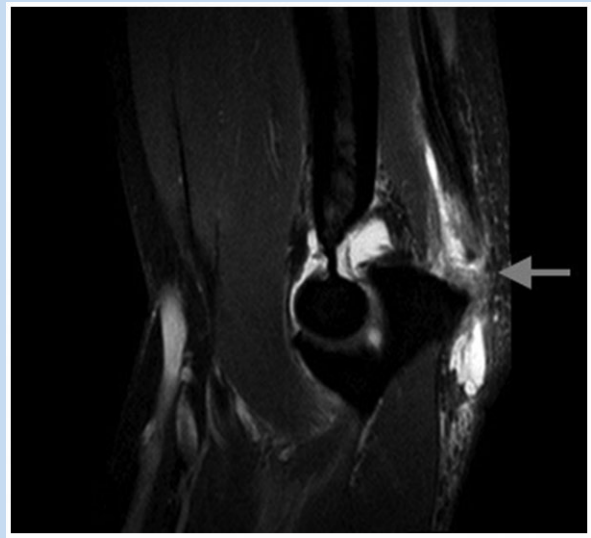

Figure 2. Magnetic resonance image showing complete triceps avulsion off the olecranon (gray arrow).

DISCUSSION

Most commonly, triceps ruptures are avulsions from the tendinous insertion at the olecranon process; however, intramuscular rupture or rupture at the myotendinous junction can also occur.[20] The most common mechanism of injury is a sudden forceful eccentric load, such as a fall onto an outstretched hand, weight lifting, or blocking in football.[8,22]

Surgical repair is generally indicated for complete triceps ruptures.[7,8,20] Both transosseous and suture anchor–based repair techniques have been described.[7,8,10,22]

There are systemic and local factors that increase a patient's risk of triceps rupture. Systemic factors include chronic renal failure with secondary hyperparathyroidism, hypocalcemic tetany, rheumatoid arthritis, osteogenesis imperfecta, corticosteroid use, anabolic steroid use, and insulin-dependent diabetes.[18,20] Locally, steroid injections, degenerative arthritis, and olecranon bursitis have been associated with increased risk of triceps tendon rupture.[13,20] Fluoroquinolone antibiotics have been associated with ruptures of other tendons and have been associated with triceps tendinopathy.[11] Fluoroquinolones are synthetic, broad-spectrum antibiotics effective at treating a variety of infections. However, they can have the undesired consequence of weakening tendons by ischemia, matrix degradation, and direct toxic changes.[6] In vitro, ciprofloxacin stimulates matrix-degrading proteolytic activity from fibroblasts and inhibits fibroblast metabolism.[21] Tenocytes incubated with levofloxacin or ciprofloxacin express increased apoptotic markers and increased matrix metalloproteinases.[17] These tendinopathic effects can present within days or up to 6 months after use of fluoroquinolones.[12] The US Food and Drug Administration (FDA) recently released a statement recommending that fluoroquinolone labels have much stronger warnings about the risks for serious adverse events, including tendinitis and tendon rupture.[2]

Physicians prescribing these medications, particularly those treating athletes, should be aware of this risk and educate their patients accordingly. Alternative antibiotic agents should be considered when treating bacterial infections in athletes. Likewise, perioperative or postoperative treatment with fluroquinolones must be carefully considered after tendon repairs.

A major limitation of this report is that we cannot determine the precise extent to which fluoroquinolone exposure contributed to these triceps ruptures and do not have histologic confirmation. Firm guidelines regarding fluoroquinolone prescriptions for athletes are lacking.

CONCLUSION

Both patients sustained triceps tendon ruptures during forceful eccentric loading after treatment with fluoroquinolone antibiotics for genitourinary conditions. Neither patient had additional local or systemic risk factors for triceps tendon rupture. These cases substantiate the FDA warnings. Alternative antibiotic agents should be considered when treating bacterial infections in athletes.

REFERENCES

1. Anzel S, Covey K, Weiner A, Lipscomb P. Disruption of muscles and tendons; an analysis of 1,014 cases. *Surgery*. 1959;45:406-414.

2. Arabyat RM, Raisch DW, McKoy JM, Bennett CL. Fluoroquinolone-associated tendon-rupture: a summary of reports in the Food and Drug Administration's adverse event reporting system. *Expert Opin Drug Saf*. 2010;14:1653-1660.
3. Bach BR, Warren RF, Wickiewicz TL. Triceps rupture: a case report and literature review. *Am J Sports Med*. 1987;15:285-289.
4. Bailey RR, Kirk JA, Peddie BA. Norfloxacin-induced rheumatic disease. *N Z Med J*. 1983;96:590.
5. Braun D, Petitpain N, Cosserat F, et al. Rupture of multiple tendons after levofloxacin therapy. *Joint Bone Spine*. 2004;71:586-587.
6. Childs SG. Pathogenesis of tendon rupture secondary to fluoroquinolone therapy. *Orthop Nurs*. 2007;26:175-182.
7. Clark J, Obopilwe E, Rizzi A, et al. Distal triceps knotless anatomic footprint repair is superior to transosseous cruciate repair: a biomechanical comparison. *Arthroscopy*. 2014;30:1254-1260.
8. Finstein JL, Cohen SB, Dodson CC, et al. Triceps tendon ruptures requiring surgical repair in National Football League players. *Orthop J Sports Med*. 2015;3:2325967115601021.
9. Karistinos A, Paulos LE. "Ciprofloxacin-induced" bilateral rectus femoris tendon rupture. *Clin J Sports Med*. 2007;17:406-407.
10. Kose O, Kilicaslan OF, Guler F, Acar B, Yuksel HY. Functional outcomes and complications after surgical repair of triceps tendon rupture. *Eur J Orthop Surg Traumatol*. 2015;25:1131-1139.
11. Le Huec JC, Schaeverbeke T, Chauveaux D, Rivel J, Dehais J, Le Rebeller A. Epicondylitis after treatment with fluoroquinolone antibiotics. *J Bone Joint Surg Br*. 1995;77:293-295.
12. Lewis T, Cook J. Fluoroquinolones and tendinopathy: a guide for athletes and sports clinicians and a systematic review of the literature. *J Athl Train*. 2014;49:422-427.
13. Mair SD, Isbell WM, Gill TJ, Schlegel TF, Hawkins RJ. Triceps tendon ruptures in professional football players. *Am J Sports Med*. 2004;32:431-434.
14. Merenda LA, Rutter L, Curran K, Kozin SH. Rupture following biceps-to-triceps tendon transfer in adolescents and young adults with spinal cord injury: an analysis of potential causes. *Top Spinal Cord Inj Rehabil*. 2012;18:197-204.
15. Mouzopoulos G, Stamatakos M, Vasiliadis G, Skandalakis P. Rupture of adductor longus tendon due to ciprofloxacin. *Acta Orthop Belg*. 2005;71:743-745.
16. Perrot S, Ziza JM, De Bourran-Cauet G, Desplaces N, Lachand AT. A new complication related to quinolones: rupture of Achilles tendon [in French]. *Presse Med*. 1991;20:1234.
17. Sendzik J, Shakibaei M, Schäfer-Korting M, Stahlmann R. Fluoroquinolones cause changes in extracellular matrix, signalling proteins, metalloproteinases and caspase-3 in cultured human tendon cells. *Toxicology*. 2005;212:24-36.
18. Stephenson AL, Wu W, Cortes D, Rochon PA. Tendon injury and fluoroquinolone use: a systematic review. *Drug Saf*. 2013;36:709-721.
19. Stinner DJ, Orr JD, Hsu JR. Fluoroquinolone-associated bilateral patellar tendon rupture: a case report and review of the literature. *Mil Med*. 2010;175:457-459.
20. Van Riet RP, Morrey BF, Ho E, O'Driscoll SW. Surgical treatment of distal triceps ruptures. *J Bone Joint Surg Am*. 2003;85:1961-1967.
21. Williams RJ III, Attia E, Wickiewicz TL, Hannafin JA. The effect of ciprofloxacin on tendon, paratenon, and capsular fibroblast metabolism. *Am J Sports Med*. 2000;28:364-369.
22. Yeh P, Stephens K, Solovyova O, et al. The distal triceps tendon footprint and a biomechanical analysis of 3 repair techniques. *Am J Sports Med*. 2010;38:1025-1033.

For reprints and permission queries, please visit SAGE's Web site at http://www.sagepub.com/journalsPermissions.nav.